

The Retinal Nerve Fiber Layer Thickness is Related to Severity of Parkinson's Disease

Kaveh Shafiei, M.D.¹, Farhad Iranmanesh, M.D.², Ali Sharifi M.D.³, Nasrin Saliminiya M.D.⁴, Tania Dehesh, Ph.D.⁵

1- Assistant Professor of Neurology, Neurology research Centre, Kerman University of Medical Sciences, Kerman, Iran
(Corresponding author; E-mail: kshafiei@gmail.com)

2- Professor of Neurology, Neurology Research Centre, Kerman University of Medical Sciences, Kerman, Iran

3- Associate Professor of Ophthalmology, Ophthalmology Department, Kerman University of Medical Sciences, Kerman, Iran

4- Neurologist, Neurology Department, Kerman University of Medical Sciences, Kerman, Iran

5- Assistant Professor of Biostatistics and Epidemiology, School of Public Health, Kerman University of Medical Sciences, Kerman, Iran

Received: 10 June, 2019

Accepted: 14 December, 2019

ARTICLE INFO

Article type:

Original Article

Keywords:

Parkinson's disease
Optical coherence tomography
Retinal nerve fiber layer thickness
Disease severity
Unified Parkinson's disease rating scale

Abstract

Introduction: We investigated correlation between the retinal nerve fiber layer (RNFL) thickness and the severity of Parkinson's disease (PD).

Methods: In this study, the RNFL thickness of 23 patients with Parkinson's disease (PD) was compared to normal controls (NCs). PD severity was assessed by the MDS-UPDRS (movement disorder society Unified Parkinson Disease Rating Scale) rating scale thoroughly in all parts. RNFL is measured by Ocular Coherent tomography (OCT). Scatter plots were used to evaluate the relationship between disease severity and retinal thickness.

Results: The findings of the study demonstrated that patients with PD had a significantly thinner average RNFL thickness compared with controls ($P=0.035$). Superior and inferior retinal quadrants were thinnest in PD compared with the healthy group ($P=0.021$ and $P=0.045$, respectively). The MDS-UPDRS had a significant reverse correlation with RNFL ($r = -0.518$, $P=0.011$) and its temporal quadrant ($r = -0.594$, $P=0.003$). Among all parts of MDS-UPDRS scale, Part III had the strongest correlation with OCT findings.

Conclusion: A correlation was found between the severity of the disease and the thinning of RNFL. MDS-UPDRS Part III subscale had the strongest correlation with RNFL thickness. Temporal quadrant RNFL became thinner as Parkinson's disease severity increased.

Introduction

Recently medical attention has been attracted to non-motor aspects of Parkinson's disease (PD). Visual information processing impairment is one of the significant non-motor symptoms which causes disability through visual hallucination and visuo-spatial disorientation (1), and could have central or peripheral defective pathophysiology (1-5).

Retinal Nerve Fiber Layer (RNFL) is connected to PD progression and disability by many studies. Since its introduction in early 1990, Optical Coherence Tomography (OCT) became a non-invasive bio-tissue imaging technique in many medical fields, including PD and similar neurodegenerative disorders (6-8).

During the past 15 years, the majority of studies showed RNFL thickness had been reduced in PD.

Inzelberg et al. were the first who conducted a study on the applicability of OCT for PD. He assessed the RNFL thickness in the peripapillary area (9). A review conducted in 2019 by Chrysou et al., concluded that neurodegeneration processes and retinal degeneration is connected (10).

So far, it is still not clearly showed that RNFL changes are related to retinal neurodegeneration, ocular complication or vascular change in PD (11-14).

OCT also could be useful in differentiating between Parkinsonian syndromes such as Multisystem Atrophy (MSA), Progressive Supranuclear Palsy (PSP) (15,16) or Dementia with Lewy body (DLB).

Few studies have suggested that there could be a correlation between RNFL and visual symptoms (for example, visual hallucinations (17) or REM behavior Disorders (RBD) (18).

The Unified Parkinson's Disease Rating Scale (UPDRS) is a quantified tools for assessing different clinical aspects of PD. It was updated in 2007 by the Movement Disorder Society (MDS). MDS-UPDRS quantifies the severity of both motor and non-motor signs and symptoms.

As far as we know, nine studies have used UPDRS in their studies on RNFL thickness and PD (19-28). However, no study has yet used MDS-UPDRS.

The aim of this study is to investigate whether there is a correlation between RNFL thickness and the severity of PD by MDS-UPDRS?

Material and Methods

23 PD patients were compared to 23 healthy controls. These patients were selected from our neurology clinic at Shafa Hospital, Kerman University of medical sciences, Iran. The study protocol was approved by the Ethics Committee at Kerman University of Medical Science (KMU). The study funded by the Neurology research Centre, KMU. The United Kingdom Brain Bank criteria for the clinical diagnosis of idiopathic PD was applied to PD diagnosis. A written informed consent was obtained from all the subjects participating in the study.

Our exclusion criteria were: acute depression according to Beck Depression Inventory-II (BDI-II) questionnaire, severe head injury, brain surgery, cerebrovascular disease and epilepsy. The Mini-Mental Status Exam score <24 was also used to identify any subject with cognitive impairment. All subject had a thoroughly ophthalmological examination. Subjects had to have a corrected visual acuity of 7/10 or better, and intraocular pressure less than 22 mmHg. Further, subjects with history of ophthalmic trauma, surgery, or posterior pole pathologies, such as age-related macular degeneration, diabetic or hypertensive retinopathy, degenerative myopia, glaucoma, or suspected glaucoma were excluded from study.

MDS-UPDRS was used to quantify the PD severity. This scale encompasses four parts: Part I concerns “non-motor experiences of daily living”; Part II concerns “motor experiences of daily living”; Part III as “motor examination” and finally Part IV for “motor complications”.

Besides MDS-UPDRS score, disease duration and Levodopa equivalent dose were recorded.

RNFL in the superior, inferior and temporal pole of retina measured by the Heidelberg Spectralis

The collected data were analyzed using SPSS software version 20.0. Differences between the distributions of demographic characteristics were evaluated using the Student t-test and correlations between the OCT findings and the MDS-UPDRS score of patients were analyzed by

linear regression. For all statistical tests, a P value<0.05 was considered statistically significant.

Results

18 subjects (78.3%) were male in each groups. There were no statistically significant differences between the mean age of PD (61.30 ± 11.57 years; range, 44–81 years) and NC (61.22 ± 11.39 ; range, 45–82 years; $P=0.981$). PD mean duration was 6.52 ± 4.08 years (range, 0–17 years) (Table 1).

Table 1. Demographic characteristics and OCT findings of patient and control groups

		PD group	control	P-value
Sex	Female n (%)	5(21.7)	5(21.7)	1
	Male n (%)	18(78.3)	18(78.3)	
	Mean \pm Standard Deviation			
Age(year)		61.30 ± 11.57	61.22 ± 11.39	0.981
RNFL (μm)		95.47 ± 10.81	101.56 ± 7.96	0.035*
Nasal		76.87 ± 12.47	74.04 ± 6.59	0.343
Temporal (μm)		71.10 ± 11.07	76.08 ± 8.69	0.091
Superior(μm)		116.56 ± 17	126.86 ± 10.02	0.021*
Inferior(μm)		117.74 ± 19.55	126.96 ± 8.69	0.045*

The study findings showed that there is RNFL thinness in PD compared to NC (87.75 to $126.75 \mu m$ (101.56 ± 7.96) in NC compared to 66.5 to $116.5 \mu m$ (95.47 ± 10.81) in PD. There was also a significant difference in the RNFL thickness of both Superior quadrant ($126.86 \pm 10.02 \mu m$ vs $116.56 \pm 17 \mu m$) and Inferior quadrant ($126.96 \pm 8.69 \mu m$ vs 117.74 ± 19.55

μm). ($P=0.021$ and $P=0.045$, between NC and PD respectively).

It was also found a correlation between MDS-UPDRS and OCT (Table 2). Considering the different parts of MDS-UPDRS, part III showed more correlation to RNFL. ($r = -0.633$, $P=0.001$). These results suggest that the higher score in PD severity is associated with the lower RNFL thickness in these peripapillary areas.

Table 2. Correlation between OCT findings, PD duration and MDS-UPDRS score in PD Group

	Part 1		Part2		Part3		Part4		MDS-UPDRS	
	r	P-value	r	P-value	r	P-value	r	P-value	r	P-value
Total OCT										
RNFL (μm)	-0.333	0.124	-0.267	0.217	-0.633	0.001*	0.055	0.802	-0.518	0.011*
Nasal	0.024	0.912	-0.315	0.144	-0.466	0.025*	0.026	0.905	-0.346	0.105
Temporal (μm)	-0.388	0.067	-0.319	0.138	-0.648	0.001*	-0.208	0.342	-0.594	0.003*
Superior(μm)	-0.165	0.451	0.006	0.977	-0.309	0.152	0.111	0.614	-0.212	0.333
Inferior (μm)	-0.376	0.077	-0.205	0.348	-0.461	0.027*	0.126	0.566	-0.397	0.061
PD duration	-0.245	0.26	0.053	0.811	-0.225	0.303	0.429	0.041*	-0.116	0.597
Levodopa dose	-0.179	0.414	0.294	0.174	-0.003	0.989	0.512	0.012*	0.01	0.647

No statistically significant correlation found between RNFL and PD duration or Levodopa dose. (Table 3)

Table 3. Correlation between RNFL, RAVG, LAVG, PD duration and Levodopa dose

	RNFL	
	R	P-value
PD duration	0.054	0.806
Levodopa dose	0.292	0.177

The scatter plot and linear regression for MDS-UPDRS mean score and RNFL mean thickness presented in Figure 1. The regression equation: MDS-

UPDRS=208.517-1.428* RNFL was developed to predict PD severity from these RNFL. According to regression model, The RNFL is responsible for 27% of the variation in the MDS-UPDRS score. We also used different regression equation between Temporal quadrant and MDS-UPDRS score: MDS-UPDRS=185.603-1.598* Temporal (Figure 2). The Temporal quadrant explains 35% of the variations in the MDS-UPDRS score according to this regression. The total RNFL and its temporal quadrant correlate nearly 50% variation on the MDS-UPDRS score. Considering MDS-UPDRS part 3, the average RNFL and the temporal quadrant explain 40%-42% of the variation respectively (Figures 3 & 4).

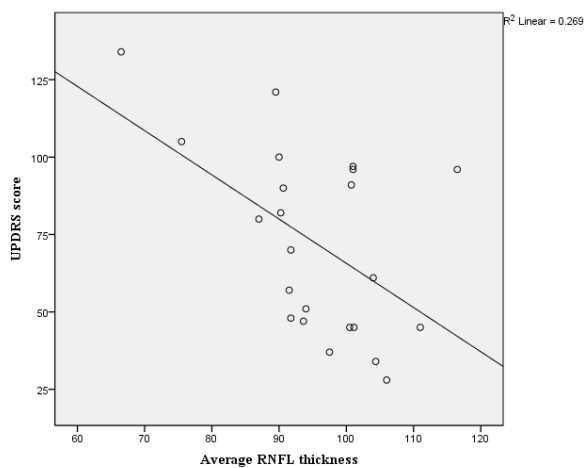


Figure 1. Scatter plot and linear regression of total MDS-UPDRS score and Average RNFL thickness

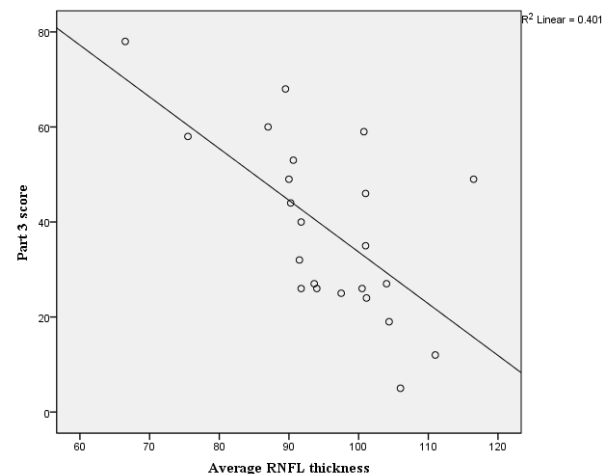


Figure 3. Scatter plot and linear regression of part III score and RNFL thickness

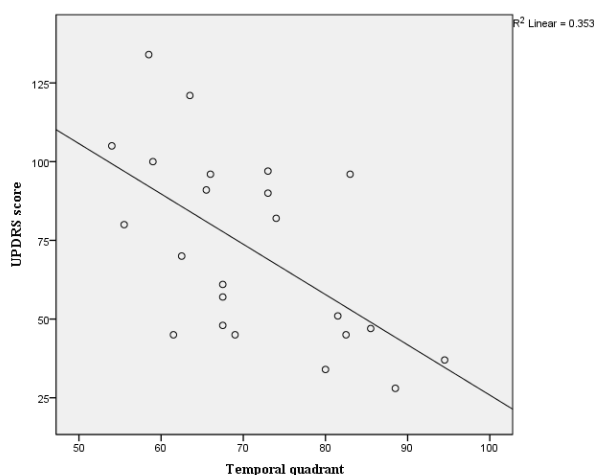


Figure 2. Scatter plot and linear regression of total MDS-UPDRS score and Temporal quadrant thickness

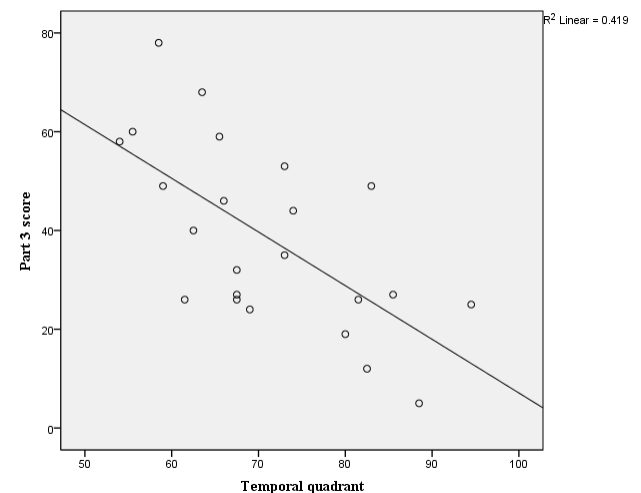


Figure 4. Scatter plot and linear regression of part III score and Temporal quadrant thickness

Discussion

Our study showed that there is possible correlation between PD severity, measured by MDS-UPDRS and decrement of Peripapillary RNFL. In PD, retinal layer thickness reduces more at temporal superior and inferior quadrants of retina. The significant correlation was observed between part III of MDS-UPDRS (Motor

examinations) and RNFL. We were not able to find any significant correlation between Part I (non-motor symptoms) and Part II (Motor symptoms of activity of daily living) and RNFL. Although more items can explain the higher correlation of the MDS-UPDRS part III at that part (33 in part III compared to 13 in Part I and II and

13, and 6 in part IV) and the emphasis of authors of this scale on motor examination.

The correlation between RNFL in PD has been investigated in many previous studies (18,24,25,29-31). PD severity was measured by less reliable tools, such as Hoen and Yahr scale (32) or UPDRS (33,34). The role of OCT in PD severity, risk of dementia and its predictive value for visual complications in follow up are also highlighted by a few studies (20,35-43) or risk of future dementia (44). These findings make OCT a valuable biomarker for the evaluation of PD patients (45-48).

In contrary to Mailankody et al., which RNFL thinness was reported to be more prominent in Macular region, our study showed that parapapillary region mostly affected (24).

According to Roth et al., many technical challenges exist in doing OCT in PD patients; mainly due to tremor or cognitive changes (21).

We also found no correlation was found between duration of Levodopa use and RNFL thickness. Our study's power was not enough to make a correlation between visual symptoms in PD and RNFL thickness. Long-term longitudinal studies are needed to confirm the

role of RNFL assessment as a biomarker of disease progression (40,42).

Conclusion

To conclude, it seems that retinal thickness reduces in PD, especially in its superior and inferior quadrants. There might be a correlation disease severity RNFL thickness. This study showed that RNFL in Temporal quadrant associates with Parkinson's disease severity. The study findings recommend OCT as a non-invasive and quantitative tool in estimating Parkinson's disease severity. It is also recommendable that the thickness of RNFL might be an acceptable indicator for progression motor disability in PD as a noninvasive technique.

Acknowledgment

We are profoundly grateful to all our subjects for devoting their time to help us complete MDS-UPDRS scale and taking OCT.

We express our gratitude to the Neurology research centre and the Student Research Committee of Kerman University of Medical Sciences.

References

1. Lee JY, Kim JM, Ahn J, Kim HJ, Jeon BS, Kim TW. Retinal nerve fiber layer thickness and visual hallucinations in parkinson's disease. *Mov Disord* 2014; 29(1):61-7.
2. Nowacka B, Lubiński W, Karczewicz D. Ophthalmological and electrophysiological features of Parkinson's disease. *Klin Oczna* 2010; 112(7-9):247-52.
3. Moschos MM, Tagaris G, Markopoulos I, Margetis I, Tsapakis S, Kanakis M, et al. Morphologic changes and functional retinal impairment in patients with Parkinson disease without visual loss. *Eur J Ophthalmol* 2011; 21(1):24-9.
4. Bodis-Wollner I, Glazman S, Yerram S. Fovea and foveation in Parkinson's disease. *Behav Neurosci* 2013; 127(2):139-50.

5. Lee JY, Ahn J, Kim TW, Jeon BS. Optical coherence tomography in parkinson's disease: is the retina a biomarker? *J Parkinsons Dis* 2014; 4(2):197-204.
6. Adam CR, Shrier E, Ding Y, Glazman S, Bodis-Wollner I. Correlation of inner retinal thickness evaluated by spectral-domain optical coherence tomography and contrast sensitivity in Parkinson disease. *J Neuroophthalmol* 2013 33(2):137-42.
7. Satue M, Garcia-Martin E, Fuertes I, Otin S, Alarcia R, Herrero R, et al. Use of fourier-domain OCT to detect retinal nerve fiber layer degeneration in parkinson's disease patients. *Eye (Lond)* 2013; 27(4):507-14.
8. Bodis-Wollner I, Miri S, Glazman S. Venturing into the no-man's land of the retina in Parkinson's disease. *Mov Disord* 2014; 29(1):15-22.
9. Inzelberg R, Ramirez JA, Nisipeanu P, Ophir A. Retinal nerve fiber layer thinning in parkinson disease. *Vision Res* 2004; 44(24):2793-7.
10. Chrysou A, Jansonius NM, van Laar T. Retinal layers in parkinson's disease: a meta-analysis of spectral-domain optical coherence tomography studies. *Parkinsonism Relat Disord* 2019; 64:40-49.
11. Eraslan M, Cerman E, Yildiz Balci S, Celiker H, Sahin O, Temel A, et al. The choroid and lamina cribrosa is affected in patients with parkinson's disease: enhanced depth imaging optical coherence tomography study. *Acta Ophthalmol* 2016; 94(1):e68-75.
12. Kromer R, Buhmann C, Hidding U, Kaserü M, Kaserü D, Hassenstein A, et al. Evaluation of retinal vessel morphology in patients with parkinson's disease using optical coherence tomography. *PLoS One* 2016; 11(8):e0161136.
13. Ferro Desideri L, Barra F, Ferrero S. Systemic and intraocular factors related to retinal thicknesses variations in patients with Parkinson's disease. *Parkinsonism Relat Disord* 2019; 61:234-5.
14. Gulmez Sevim D, Unlu M, Sonmez S, Gultekin M, Karaca C, Ozturk Oner A. Retinal vessel diameter obtained by optical coherence tomography is spared in parkinson's disease. *Int Ophthalmol* 2019; 39(4):813-9.
15. Schneider M, Müller HP, Lauda F, Tumani H, Ludolph AC, Kassubek J, et al. Retinal single-layer analysis in parkinsonian syndromes: an optical coherence tomography study. *J Neural Transm (Vienna)* 2014; 121(1):41-7.
16. Gulmez Sevim D, Unlu M, Gultekin M, Karaca C, Mirza M, Mirza GE. Evaluation of retinal changes in progressive supranuclear palsy and parkinson disease. *J Neuroophthalmol* 2018; 38(2):151-5.
17. Bernardin F, Schwan R, Lalanne L, Ligier F, Angioi-Duprez K, Schwitzer T, et al. The role of the retina in visual hallucinations: a review of the literature and implications for psychosis. *Neuropsychologia* 2017; 99:128-38.
18. Yang ZJ, Wei J, Mao CJ, Zhang JR, Chen J, Ji XY, et al. Retinal nerve fiber layer thinning: a window into rapid eye movement sleep behavior disorders in Parkinson's disease. *Sleep Breath* 2016; 20(4):1285-92.
19. Bayhan HA, Aslan Bayhan S, Tanık N, Gürdal C. The association of spectral-domain optical coherence tomography determined ganglion cell complex parameters and disease severity in Parkinson's disease. *Curr Eye Res* 2014; 39(11):1117-22.
20. Jiménez B, Ascaso FJ, Cristóbal JA, López del Val J. Development of a prediction formula of Parkinson disease severity by optical coherence tomography. *Mov Disord* 2014; 29(1):68-74.

21. Roth NM, Saidha S, Zimmermann H, Brandt AU, Isensee J, Benkhellouf-Rutkowska A, et al. Photoreceptor layer thinning in idiopathic Parkinson's disease. *Mov Disord* 2014; 29(9):1163-70.
22. Sen A, Tugcu B, Coskun C, Ekinici C, Nacaroglu SA. Effects of levodopa on retina in parkinson disease. *Eur J Ophthalmol* 2014; 24(1):114-9.
23. Li L, Ji X, Mao C, Chen Y, Guo S, Li S, et al. A clinical study of changes in retina and visual field in patients with early Parkinson's disease. *Zhonghua Nei Ke Za Zhi* 2015; 54(6):521-4. [In Chinese].
24. Mailankody P, Battu R, Khanna A, Lenka A, Yadav R, Pal PK, et al. Optical coherence tomography as a tool to evaluate retinal changes in parkinson's disease. *Parkinsonism Relat Disord* 2015; 21(10):1164-9.
25. Aydin TS, Umit D, Nur OM, Fatih U, Asena K, Nefise OY, et al. Optical coherence tomography findings in Parkinson's disease. *Kaohsiung J Med Sci* 2018; 34(3):166-71.
26. Brandt AU, Zimmermann HG, Oberwahrenbrock T, Isensee J, Müller T, Paul F, et al. Self-perception and determinants of color vision in Parkinson's disease. *J Neural Transm (Vienna)* 2018; 125(2):145-52.
27. Matlach J, Wagner M, Malzahn U, Schmidtman I, Steigerwald F, Musacchio T, et al. Retinal changes in parkinson's disease and glaucoma. *Parkinsonism Relat Disord* 2018; 56:41-6.
28. Yıldız D, Pekel NB, Yener NP, Seferoğlu M, Günes A, Sığırlı D. Assessment of neurodegeneration by optical coherence tomography and mini-mental test in parkinson's disease. *Ann Indian Acad Neurol* 2019; 22(2):212-6.
29. Stemplewitz B, Keserü M, Bittersohl D, Buhmann C, Skevas C, Richard G, et al. Scanning laser polarimetry and spectral domain optical coherence tomography for the detection of retinal changes in parkinson's disease. *Acta Ophthalmol* 2015; 93(8):e672-7.
30. Pilat A, McLean RJ, Proudlock FA, Maconachie GD, Sheth V, Rajabally YA, et al. In vivo morphology of the optic nerve and retina in patients with parkinson's disease. *Invest Ophthalmol Vis Sci* 2016; 57(10):4420-7.
31. Sengupta P, Dutta K, Ghosh S, Mukherjee A, Pal S, Basu D, et al. Optical coherence tomography findings in patients of parkinson's disease: an indian perspective. *Ann Indian Acad Neurol* 2018; 21(2):150-5.
32. Litvinenko IV, Dynin PS, Trufanov AG, Gimadutdinov RF, Maltsev DS. Eye as an object of investigation of cognitive impairment in Parkinson's disease. *Zh Nevrol Psikhiatr Im S S Korsakova* 2018; 118(6. Vyp. 2):105-14. [In Russian].
33. Garcia-Martin E, Rodriguez-Mena D, Satue M, Almarcegui C, Dolz I, Alarcia R, et al. Electrophysiology and optical coherence tomography to evaluate parkinson disease severity. *Invest Ophthalmol Vis Sci* 2014; 55(2):696-705.
34. Eraslan M, Balci SY, Cerman E, Temel A, Suer D, Elmaci NT. Comparison of optical coherence tomography findings in patients with primary open-angle glaucoma and parkinson disease. *J Glaucoma* 2016; 25(7):e639-46.
35. Cubo E, López Peña MJ, Diez-Feijo Varela E, Pérez Gil O, Garcia Gutierrez P, Araus González E, et al. Lack of association of morphologic and functional retinal changes with motor and non-motor symptoms severity in Parkinson's disease. *J Neural Transm (Vienna)* 2014; 121(2):139-45.
36. Satue M, Seral M, Otin S, Alarcia R, Herrero R, Bambo MP, et al. Retinal thinning and correlation

- with functional disability in patients with Parkinson's disease. *Br J Ophthalmol* 2014; 98(3):350-5.
37. Yu JG, Feng YF, Xiang Y, Huang JH, Savini G, Parisi V, et al. Retinal nerve fiber layer thickness changes in parkinson disease: a meta-analysis. *PLoS One* 2014; 9(1):e85718.
 38. Sari ES, Koc R, Yazici A, Sahin G, Ermis SS. Ganglion cell-inner plexiform layer thickness in patients with Parkinson disease and association with disease severity and duration. *J Neuroophthalmol* 2015; 35(2):117-21.
 39. Slotnick S, Ding Y, Glazman S, Durbin M, Miri S, Selesnick I, et al. A novel retinal biomarker for Parkinson's disease: quantifying the foveal pit with optical coherence tomography. *Mov Disord* 2015; 30(12):1692-5.
 40. Satue M, Obis J, Rodrigo MJ, Otin S, Fuertes MI, Vilades E, et al. Optical coherence tomography as a biomarker for diagnosis, progression, and prognosis of neurodegenerative diseases. *J Ophthalmol* 2016; 2016: 8503859.
 41. Ucak T, Alagoz A, Cakir B, Celik E, Bozkurt E, Alagoz G, et al. Analysis of the retinal nerve fiber and ganglion cell - Inner plexiform layer by optical coherence tomography in Parkinson's patients. *Parkinsonism Relat Disord* 2016; 31:59-64.
 42. Satue M, Rodrigo MJ, Obis J, Vilades E, Gracia H, Otin S, et al. Evaluation of progressive visual dysfunction and retinal degeneration in patients with parkinson's disease. *Invest Ophthalmol Vis Sci* 2017; 58(2):1151-7.
 43. Polo V, Satue M, Rodrigo MJ, Otin S, Alarcia R, Bambo MP, et al. Visual dysfunction and its correlation with retinal changes in patients with Parkinson's disease: an observational cross-sectional study. *BMJ Open* 2016; 6(5):e009658.
 44. Pillai JA, Bermel R, Bonner-Jackson A, Rae-Grant A, Fernandez H, Bena J, et al. Retinal nerve fiber layer thinning in alzheimer's disease: a case-control study in comparison to normal aging, parkinson's disease, and non-alzheimer's dementia. *Am J Alzheimers Dis Other Dement* 2016; 31(5):430-6.
 45. Archibald NK, Clarke MP, Mosimann UP, Burn DJ. Retinal thickness in parkinson's disease. *Parkinsonism Relat Disord* 2011; 17(6):431-6.
 46. Tian T, Zhu XH, Liu YH. Potential role of retina as a biomarker for progression of parkinson's disease. *Int J Ophthalmol* 2011; 4(4):433-8.
 47. Bodis-Wollner I. Foveal vision is impaired in Parkinson's disease. *Parkinsonism Relat Disord* 2013; 19(1):1-14.
 48. Kirbas S, Turkyilmaz K, Tufekci A, Durmus M. Retinal nerve fiber layer thickness in parkinson disease. *J Neuroophthalmol* 2013; 33(1):62-5.